

REVIEW ARTICLE



Peripheral ossifying fibroma in a pediatric patient: A case report with review of the literature

N. B. Nagaveni, Rupali Sharma, Dhanya Sanalkumar, P. Poornima

Department of Pedodontics and Preventive Dentistry, College of Dental Sciences, Davangere, Karnataka, India

Correspondence

Dr. N. B. Nagaveni, Department of Pedodontics and Preventive Dentistry, College of Dental Sciences, Davangere, Karnataka, India. Email: nagavenianurag@gmail.com

Received 12.12.2014;
Accepted 16.01.2015

doi: 10.15713/ins.ijcdmr.18

How to cite the article:

N. B. Nagaveni, Rupali Sharma, Dhanya Sanalkumar, P. Poornima, "Peripheral ossifying fibroma in a pediatric patient: A case report with review of literature," Int J Contemp Dent Med Rev, vol. 2014, Article ID 051214, 2014. doi: 10.15713/ins.ijcdmr.18.

Abstract

A peripheral ossifying fibroma (POF) is a benign fibro-osseous lesion of a reactive rather than a neoplastic nature, whose pathogenesis is uncertain. Repeated clinic-pathological studies on the POF have not addressed the pediatric population in specific detail. This case is probably the few discovered which demonstrates POF in a pediatric patient.

Key words: Gingiva, peripheral ossifying fibroma, surgical excision

Introduction

Many types of localized reactive lesions may occur on the gingiva including focal fibrous hyperplasia, pyogenic granuloma, peripheral giant cell granuloma and peripheral ossifying fibroma (POF). POF is typically a solitary, slow growing, nodular mass, which may be either pedunculated or sessile.^[1] Solitary gingival enlargements in children are a relatively common finding. Usually, these enlargements are a response to local irritation. POF is one such reactive lesion.^[2]

POF is often composed of a cellular fibroblastic connective – tissue stroma associated with the formation of randomly dispersed foci of a mineralized product consisting of either bone, cementum like tissue or dystrophic calcifications.^[2] This may be the reason why in the literature, this pathologic lesion sometimes has been described as an ossifying fibroid epulis, a peripheral fibroma with calcification or a calcifying granuloma. However, in 1982, Gardner recommended that the only term used to describe this lesion should be POF.^[3]

POF usually measures <1.5 cm in diameter, but patients with a lesion of 6 cm and 9 cm have also been reported. Etiology and pathogenesis of POF remains unknown. Some investigators consider it as a neoplastic process, whereas others consider it as a reactive process. In either case, the lesion is thought to arise from

cells in the periodontal ligament. Trauma or local irritants such as dental plaque, calculus, micro-organisms, masticatory forces and poor quality restorations have been implicated in etiology of POF.^[1]

Case Report

A 13-year-old male patient reported to the Department of Pedodontics and Preventive Dentistry complaining of soft tissue growth in the upper front teeth region since 1 year. The swelling was of smaller than peanut size when he noticed for the first time and gradually increased to reach the present size. There was no history of trauma to the same region. The medical status was non-contributory, and family history was not significant. On intra-oral examination, a soft tissue swelling was found between maxillary central incisors attached to the gingiva. The growth was firm in consistency, pedunculated, solitary and pinkish in color with no associated pain [Figure 1]. It measured about 7 mm × 8 mm diameter and tends to bleed while brushing. Periapical radiographic examination revealed both central incisors with normal periodontal ligament space and periradicular architecture [Figure 2]. The case was provisionally diagnosed as irritation fibroma, and surgical excision of the same

lesion was planned. After obtaining signed informed consent, the growth was surgically excised under local anesthesia. Following excision profuse bleeding was noticed, and this was controlled using cotton pack for few minutes [Figure 3]. The excised specimen was sent for histopathological examination and finally diagnosed as POF based on both clinical and histological features [Figure 4]. Patient was kept under observation and followed up after 3 months with no recurrence in the lesion [Figure 5].

Discussion

Intraoral ossifying fibromas have been described in the literature since 1940s. Many names have been given to similar lesions such as epulis, peripheral fibroma with calcification, POFs, calcifying fibroblastic granuloma, peripheral cementifying fibroma, peripheral fibroma with cemento-genesis and peripheral cement-ossifying fibroma.^[4] All the terminologies are appropriate for this tumor as they may contain a variety of calcified material. When bone predominates in the lesion, the term “ossifying” is used.

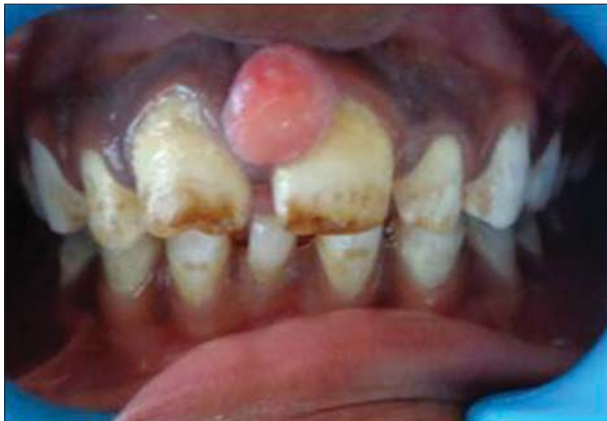

Figure 1: Intra oral picture showing soft tissue growth between maxillary central incisors

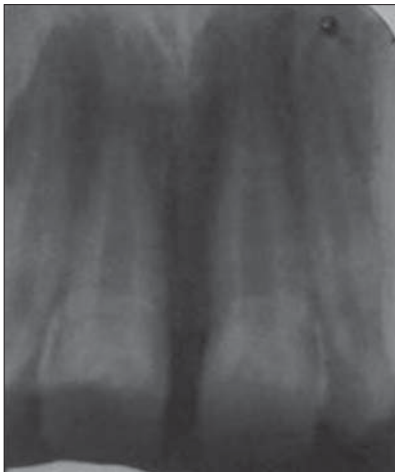

Figure 2: Periapical radiograph showing teeth with normal periradicular architecture

The term “cementifying” has been assigned when the curvilinear, trabecular or spherical calcifications are encountered. However, when both cementum and bone-like tissues are observed the lesions are then referred to as cement-ossifying fibroma.^[1]

POF represents a common gingival growth, usually arising from the interdental papilla and representing up to 2% of all

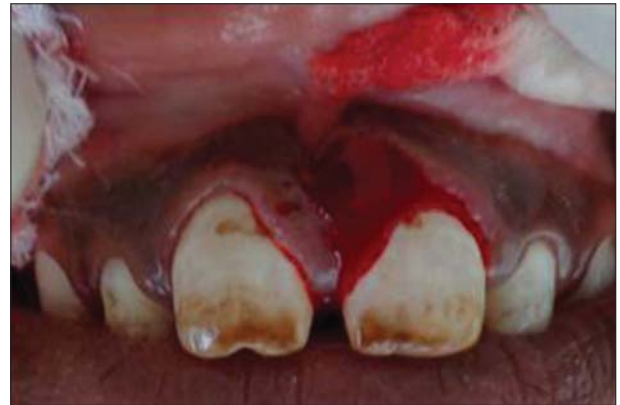

Figure 3: Intraoperative view

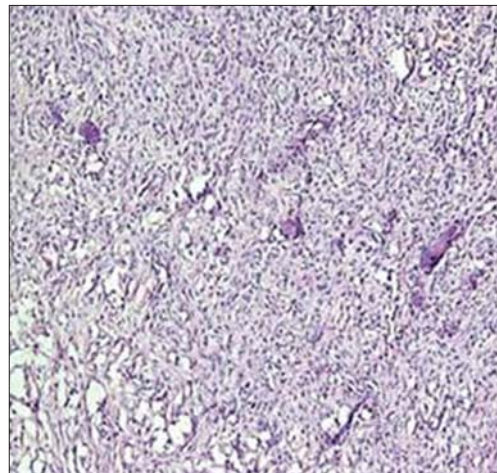


Figure 4: Fibrous tissue with minimal areas of eosinophilic osteoid (H and E, ×100)

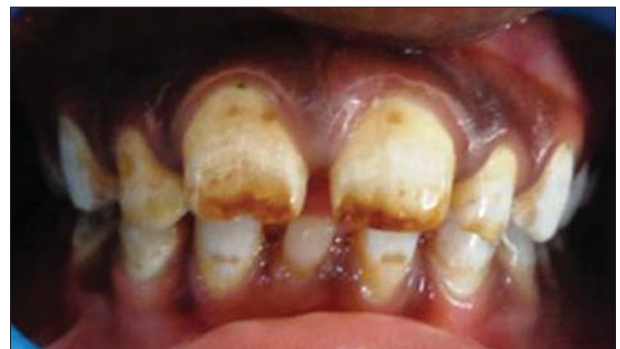

Figure 5: Six months follow-up showing no recurrence

lesions that are biopsied.^[5] In pediatric patient studies, the incidence of POFs in biopsied lesions ranged from 1% to 2%.^[6]

The main etiological factors of POF are trauma and chronic irritation, particularly from sub-gingival plaque and calculus. Furthermore, trauma or local irritants such as ill-fitting dental appliances and poor quality dental restorations play a significant role in the etiology and pathogenesis.^[2] Eversole *et al.*^[7] stated that the constant irritation present during exfoliation of deciduous teeth and eruption of the permanent teeth may also result in an increased incidence of reactive lesions, which originate from the periodontal ligament. This hypothesis is based on the fact that POFs arise exclusively on the gingiva, the subsequent proximity of the gingiva to the periodontal ligament and the inverse co-relation between age distribution of patients presenting with the POFs and the number of missing teeth with associated periodontal ligament [Table 1].^[4] Clinically, POFs present as exophytic, smooth surfaced pink or red nodular mass that is sessile or is less frequently seen on a pedicle.

Ossifying fibromas occur from craniofacial bones and is generally categorized into two types, central and POFs. The central type arises from the endosteum or the periodontal ligament adjacent to the root apex and expands from the

medullary cavity of the bone. On the other hand, the peripheral type shows a contiguous relationship with the periodontal ligament, occurring solely on the soft tissue. POF is not peripheral counterpart of the central ossifying fibroma. Inflammatory hyperplasia originating in the superficial periodontal ligament is considered to be a factor in the histogenesis of POF.^[8]

Ossifying fibromas may occur at any age, but are more common in young adults. A variant of ossifying fibroma, juvenile (aggressive) ossifying fibroma, has been described in children and young adults who are younger than 15 years of age.^[1] While POF occurrence is uncommon in the neonate, it is not difficult to rationalize that the active growth of alveolar bone in the neonatal jaw, when stimulated by removal of neonatal tooth, might respond with an exuberant periosteal response and form a reactive lesion.^[3] Females are more commonly affected than males. High female predilection, a rare occurrence in the first decade, and decline in incidence after age 30 suggest that the hormonal influence maybe a lesional growth factor.^[2] According to Buchner and Hansen, POFs occurred 60% of the time in maxilla and 40% in the mandible, and 54% occurred in the incisor/cuspid region.^[9]

Histologically, these lesions are fibro-osseous in nature. They are composed of cellular fibrous tissue with areas of fibro-vascular tissue that often contain an inflammatory component with abundant plasma cells. Ossification is usually seen in the cellular zone and shows a considerable variation both quantitatively and qualitatively. From small rounded calcified deposits to large trabecular bone areas surrounded by osteoblasts may be observed. The predominant cell of this lesion is a bland spindle cell. Mitotic figures are rare. Admixed in the fibrous background are irregularly shaped osseous. The histopathological hematoxylin and eosin stained section of lesion revealed a well-circumscribed, encapsulated mass; the capsule was fibrous and thinned out at places. The subcapsular area comprised interconnected bony trabeculae encasing plump osteocytes with most of the trabeculae exhibiting osteoblastic rimming. Concentric lamellated and spherical ossicles were seen with a basophilic center and peripheral eosinophilic mass. The fibrous tissue is of varying cellularity with few chronic inflammatory cells.^[1]

The recommended treatment of POF is a local surgical excision that extends to include the periosteum with submission for histopathological examination.^[10] Local resection is done with peripheral and deep margins including both the periodontal ligament and the affected periosteal component. In addition, elimination of local etiological factors such as plaque and tartar is required.^[1]

Recurrence rates of 8-20% have been reported. When taking in account, the reactive nature of the lesion, this rate of recurrence may reflect incomplete excision or repeated injury.^[3]

Conclusion

A POF is a slowly progressing lesion, the growth of which is generally limited. Many cases will progress for long periods

Table 1: Comprehensive review of literature regarding etiology of peripheral ossifying fibroma

Year	Author	Clinical findings
1982	Gardner ^[11]	Clinically present as hyperplastic growth of tissues that is unique to the gingival mucosa
1989	Buchner and Hansen ^[9]	Rare, benign, un-encapsulated, exophytic gingival mass of fibrous connective tissue. Early POFs present as ulcerated nodules with little calcification, allowing easy misdiagnosis
2001	Carrera Grañó <i>et al.</i> ^[12]	POFs present as well circumscribed, hard, pedunculated, exophytic tumor mass measuring 2 cm in size, and do not show any ulceration
2006	Kumar <i>et al.</i> ^[5]	Both maxillary and mandibular gingiva are affected and the growths appear as nodular masses with erythematous, ulcerated surfaces, measuring 5mm to 3 cm in diameter
2006	Neville <i>et al.</i> ^[10]	Found that metastatic lesions can also manifest as gingival masses in the hard and soft palates
2009	Nonaka <i>et al.</i> ^[13]	A painless exophytic mass located in the mandibular gingiva
2011	Mishra <i>et al.</i> ^[14]	Comprises of the growth that occurs in the mandibular region, with displacement of anterior teeth
2013	Verma <i>et al.</i> ^[15]	Presented a series of cases of peripheral cement-ossifying fibroma emphasizing the differential diagnosis
2013	Childers <i>et al.</i> ^[16]	A self-limiting, sessile or pedunculated, gingival nodule typically <2 cm, but can grow large and can displace teeth as well

POF: Peripheral ossifying fibroma

before the patient seeks treatment, because of lack of symptoms associated with it. The treatment of these focal reactive overgrowths is complete excision and most importantly, regular follow-up should be established to check for any recurrence.

References

1. Trasad VA, Devarsa GM, Subba Reddy VV, Shashikiran ND. Peripheral ossifying fibroma in the maxillary arch. *J Indian Soc Pedod Prev Dent* 2011;29:255-9.
2. Cuisia ZE, Brannon RB. Peripheral ossifying fibroma – a clinical evaluation of 134 pediatric cases. *Pediatr Dent* 2001;23:245-8.
3. Kohli K, Christian A, Howell R. Peripheral ossifying fibroma associated with a neonatal tooth: case report. *Pediatr Dent* 1998;20:428-9.
4. Khan FY, Jan SM, Mushtaq M. Multicentric peripheral ossifying fibroma: A case report and review of the literature. *J Indian Soc Periodontol* 2013;17:648-52.
5. Kumar SK, Ram S, Jorgensen MG, Shuler CF, Sedghizadeh PP. Multicentric peripheral ossifying fibroma. *J Oral Sci* 2006;48:239-43.
6. Das S, Das AK. A review of pediatric oral biopsies from a surgical pathology service in a dental school. *Pediatr Dent* 1993;15:208-11.
7. Eversole LR, Sabes WR, Rovin S. Fibrous dysplasia: a nosologic problem in the diagnosis of fibro-osseous lesions of the jaws. *J Oral Pathol* 1972;1:189-220.
8. Moon WJ, Choi SY, Chung EC, Kwon KH, Chae SW. Peripheral ossifying fibroma in the oral cavity: CT and MR findings. *Dentomaxillofac Radiol* 2007;36:180-2.
9. Buchner A, Hansen LS. The histomorphologic spectrum of peripheral ossifying fibroma. *Oral Surg Oral Med Oral Pathol* 1987;63:452-61.
10. Neville BW, Damm DD, Allen CM, Bouquot JE. *Oral and Maxillofacial Pathology*. Philadelphia: WB Saunders Co; 1995. p. 374-6.
11. Gardner DG. The peripheral odontogenic fibroma: an attempt at clarification. *Oral Surg Oral Med Oral Pathol* 1982;54:40-8.
12. Carrera Grañó I, Berini Aytés L, Escoda CG. Peripheral ossifying fibroma. Report of a case and review of the literature. *Med Oral* 2001;6:135-41.
13. Nonaka CF, Pacheco DF, Nunes RP, Freitas Rde A, Miguel MC. Ossifying fibromyxoid tumor in the mandibular gingiva: case report and review of the literature. *J Periodontol* 2009;80:687-92.
14. Mishra MB, Bhishen KA, Mishra S. Peripheral ossifying fibroma. *J Oral Maxillofac Pathol* 2011;15:65-8.
15. Verma E, Chakki AB, Nagaral SC, Ganji KK. Peripheral cemento-ossifying fibroma: case series literature review. *Case Rep Dent* 2013;2013:930870.
16. Childers EL, Morton I, Fryer CE, Shokrani B. Giant peripheral ossifying fibroma: a case report and clinicopathologic review of 10 cases from the literature. *Head Neck Pathol* 2013;7:356-60.